J Neuropathol Exp Neurol
Vol. 00, No. 0, 2020, pp. 1–5
doi: 10.1093/jnen/nlaa144

OXFORD

LETTER TO THE EDITOR

Heterogeneous Pattern of Differentiation With BCAS1/NABC1 Expression in a Case of Oligodendroglioma

María José Ulloa-Navas, MSc[1], Luis Rubio, PhD[2], Anna Teruel-Sanchis, MSc[1], Jorge Peña-Peña, BSc[1], José Manuel García-Verdugo, PhD[1], Vicente Herranz-Pérez, PhD[1,3], and Jaime Ferrer-Lozano, MD

Laboratory of Comparative Neurobiology, Cavanilles Institute of Biodiversity and Evolutionary Biology, Universitat de València, CIBERNED, Valencia, Spain
Department of Pathology, Hospital Universitari i Politècnic La Fe, Valencia, Spain
Predepartamental Unit of Medicine, Faculty of Health Sciences, Universitat Jaume I, Castelló de la Plana, Spain

Correspondence to: Vicente Herranz-Pérez, Institute Cavanilles of Biodiversity and Evolutionary Biology, Laboratory of Comparative Neurobiology, C/ Catedrático José Beltrán Martínez, 2, 46980 Paterna, Valencia, Spain; E-mail: vicente.herranz@uv.es

To the Editor:

Oligodendrogliomas (ODGs) have been defined as *IDH*-mutant, 1p/19q-codeleted diffuse gliomas by the 2016 WHO Classification of Tumours of the Central Nervous System (1–3). The histogenesis underlying gliomas is still elusive, and the cell of origin for gliomas has not been clearly defined. However, glial progenitors have been suggested as possible candidates for malignant glioma generation (4). Moreover, NG2-glia and PDGFRα-expressing oligodendrocyte progenitors (OPCs) have been identified in some astrocytomas and ODGs as a direct evidence of tumorigenesis originating from these cell types (5, 6). More recent research based on genetic evidence indicates that ODGs may not have a unique cell of origin, but that they can arise from ventricular-subventricular zone-like stem cells, oligodendrocyte or astrocyte progenitor cells (7).

The study of ODG cellular heterogeneity may offer further insight into the complexity of tumor constituents and how they might influence the malignant behavior. To better understand this aspect, state-of-the-art multi-omics studies (8, 9) have subclassified 1p/19q-codeleted diffuse gliomas into different inter and intratumoral populations, according to the genomic features they display, or the common markers that tumor cells share with immature ventricular-subventricular zone cells (i.e. oligodendrocytes, OPCs, neuronal precursors, or stem cells). These analyses show that in anaplastic ODGs there is a subpopulation of cells that express OPC markers and exhibit more aggressive behavior due to *MYC* upregulation (8).

Therefore, to improve our current understanding of the histogenesis and diversity of ODG biology, new markers of differentiation should be studied. Herein, we describe a remarkable case of an ODG presenting diverse histologic features and phenotypic heterogeneity labeled with the novel marker BCAS1/NABC1 (brain enriched myelin associated protein 1, encoded by *BCAS1* gene located on 20q13.2). BCAS1 expression has been recently proposed as a marker that defines a discrete maturation stage of oligodendrocytes in the human brain (10). BCAS1-positive cells or premyelinating oligodendrocytes have been studied in the white matter of nonpathologic brains and in the brain of multiple sclerosis patients, but not as a marker of a specific population within an ODG. Therefore, to our knowledge, this is the first report of discrete, clustered BCAS1-positive nodules in a glioma.

A casual finding was made in a neurologically asymptomatic 65-year-old woman, who underwent MRI examination prior to oral surgery. Clinical history revealed a thalamic stroke. The patient presented a T2-hyperintense, noncontrast-enhancing mass in her right frontal lobe, measuring 55 mm in greatest dimension, surrounded by edema. A complete en bloc surgical resection was performed. The patient has been free of disease for 2 years following adjuvant chemoradiotherapy.

Histopathologic analysis disclosed a heterogeneous picture (Fig. 1A), with a main component of classical ODG, growing diffusely in sheets of tightly packed uniform tumor cells with scant cytoplasm, round nuclei, and perinuclear clear halos. The tumor harbored very few mitotic figures. Rounded microcalcifications were seen within the tumor sheets. These cells diffusely invaded the adjacent cortex, showing perineuronal and perivascular satellitosis. On the other hand, small, relatively well-defined nodules were seen in the superficial white matter. These nodules were in direct transition with the diffuse, sheet-like cortical tumor growth. They displayed a loosely cohesive tumor cell population, embedded in a microvacuolated background. These cells showed more abundant and vacuolated cytoplasm, and moderately pleomorphic nuclei with irregular contour and rare mitoses. Together with the previous patterns, tumor cells invaded the subcortical white matter forming rows or ill-defined columns, as well as vague rosettes.

Immunohistochemical assessment showed expression of mutant IDH1 (R132H) protein in all tumor areas (Fig. 1B),

© 2020 American Association of Neuropathologists, Inc. All rights reserved.

Downloaded from https://academic.oup.com/jnen/advance-article/doi/10.1093/jnen/nlaa144/6129327 by Universidad de Valencia user on 08 February 2021

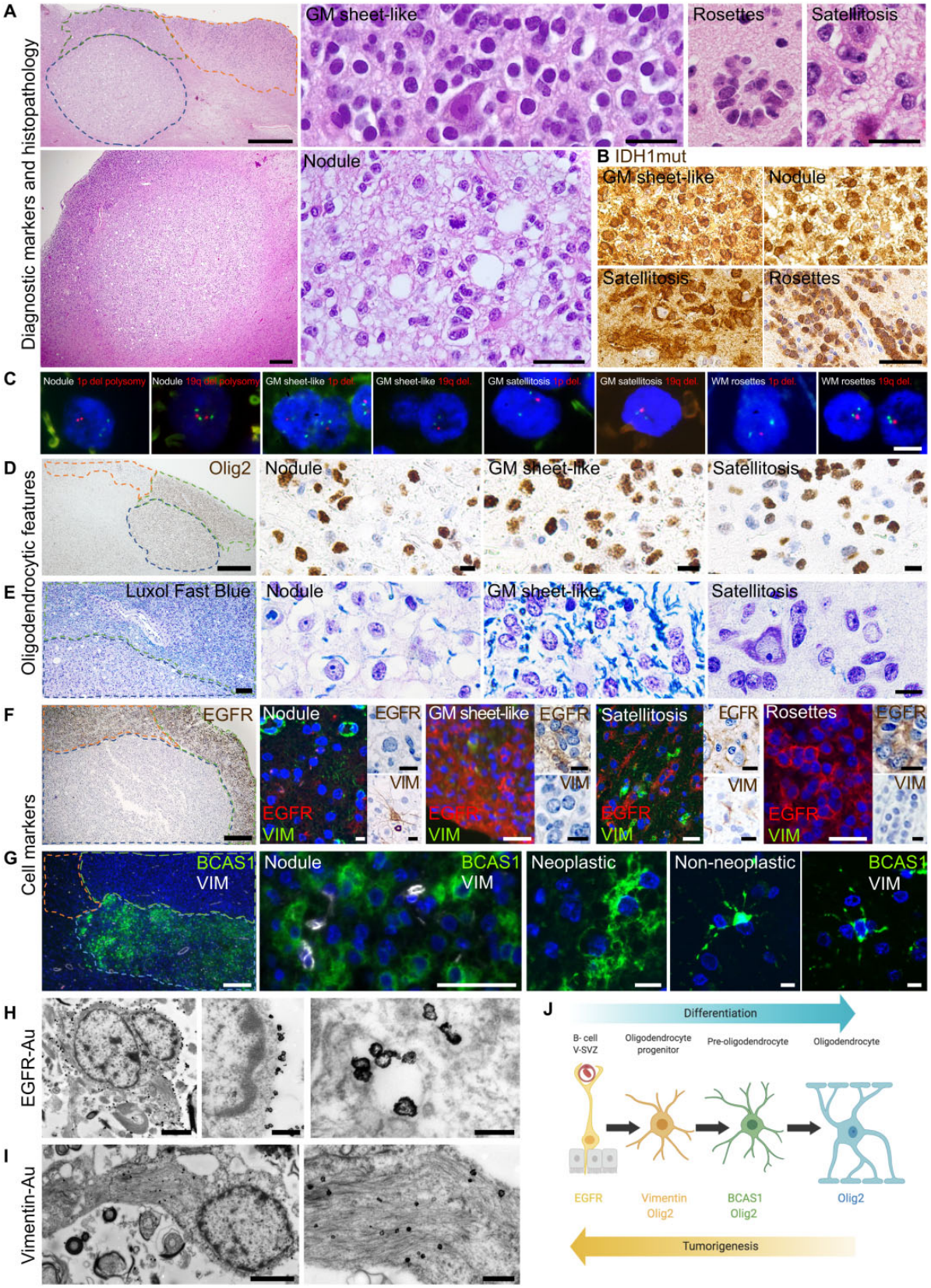

FIGURE 1. Histological and molecular characterization of the different cell types within the tumor. **(A)** Hematoxylin and eosin staining of the tumor. The area surrounded by a blue dotted line corresponds to the nodule, the area surrounded by a green

Downloaded from https://academic.oup.com/jnen/advance-article/doi/10.1093/jnen/nlaa144/6129327 by Universidad de Valencia user on 08 February 2021

indicating the *IDH*-mutant status, together with preservation of ATRX staining (not shown). All neoplastic populations disclosed 1p/19q-codeletion by FISH analysis, with a fraction of tumor cells showing polysomy (Fig. 1C). Olig-2 positivity was also uniformly detected throughout the tumor (Fig. 1D). A final diagnosis of ODG, *IDH*-mutated, 1p/19q-codeleted, WHO grade II was rendered. Molecular analysis revealed a mutation in *TERT* promoter region, c.-146C > T (C250T), and an *MGMT*-methylated status. In order to better characterize the different tumor cell populations, further immunohistochemistry, immunofluorescence, and transmission electron microscopy studies were performed (Table).

The diffuse, main sheet-like tumor component showed a highly aberrant myelination pattern. The myelination observed through Luxol fast blue staining displayed hypermyelination in the whole area (Fig. 1E). A strong expression of EGFR (Fig. 1F), with a negative staining against vimentin, PDGFRa, and NG2 was observed. Neuronal markers (NeuN, synaptophysin) were also negative. Immunofluorescence study proved the absence of BCAS1 expression in this fraction of tumor cells (Fig. 1G). Immunoelectron microscopy for EGFR showed cells with abundant intermediate filaments, rough endoplasmic reticulum and mitochondria. EGFR expression was associated with the plasma membrane and endocytic vesicles (Fig. 1H).

The small nodules located in the superficial white matter, on the other hand, showed hypomyelination (Fig. 1E). A rather different protein expression profile was noted, with absence of EGFR and PDGFRa staining and a strong reactivity against BCAS1, displaying small nuclei and a cytoplasmic pattern that was very different from that observed in the nonneoplastic cells in the white matter (Fig. 1F, G). Neuronal and other OPC markers (Table) proved negative. Ultrastructural examination showed vimentin-positive cells with long processes contacting blood vessels (Fig. 1I).

The area composed of perivascular and perineuronal satellitosis in the cortex, adjacent to the diffuse gray matter infiltration, exhibited scaffolding ramified vimentin-positive cells contacting the blood vessels, and invasive EGFR-positive cells (Fig. 1F). Moreover, this subset of the lesion was GFAP-negative and its cellular composition was different from those seen in the cortical sheet-like and white matter nodular components. The rosettes scattered through the white matter, on the other hand, were also EGFR-positive but did not exhibit vimentin expression. Other evaluated markers are shown in the Table.

Altogether, this tumor can be considered a remarkable entity of cellular heterogeneity, combined with an example of differentiation mimicry performed by neoplasias. Specifically, the complex heterogeneity that recapitulates the natural differentiation of oligodendrocytes (Fig. 1J) is demonstrated. The intermingled vimentin-positive cells present between BCAS- or EGFR-positive cells have been described as more immature glial progenitors linked to gliomas (11, 12). The difference in cellular size and morphology of the different vimentin-positive cells in our case could be related to the different tumor cell density of the various growth patterns. On the other hand, the presence of internal vesicles labeled with EGFR could demonstrate the activation of the receptor. In the diffuse area of the tumor, EGFR expression and its associated myelination replicate the phenotype observed in human progenitors (13, 14). Although the patterns of myelination and BCAS1 expression, together with the cellular morphology of neoplastic cells, were very different from what has been previously described (10) and from those of the cells observed in the neighboring nonneoplastic white matter, we consider that the expression of this marker imitates the myelinating pre-oligodendrocyte stage. As such, the presence of a BCAS1-positive tumor cell subpopulation might be relevant to exploring the ways that could promote differentiation in OPC-derived gliomas (15).

FUNDING

This study was supported by the Valencian Council for Innovation, Universities, Science and Digital Society

FIGURE 1.. Continued
dotted line corresponds to the diffuse sheet-like tumor component, the area surrounded by an orange dotted line corresponds to the satellitosis present in the cortex. This shows the cellular heterogeneity in this oligodendroglioma. **(B)** Oligodendroglioma IDH1 (R132H) mutation labels all the tumoral populations. **(C)** 1p/19q-codeletion in all the areas corroborates the diagnosis of oligodendroglioma. A fraction of neoplastic cells in the nodule exhibits polysomy. **(D)** Olig2 immunohistochemistry reveals an intense staining in all the areas, showing the oligodendroglial nature of this tumor. **(E)** Luxol fast blue staining showing the abnormal pattern of myelination in this tumor. The nodular area exhibits a pattern of hypomyelination while the spreading sheet-like zone shows a pattern of hypermyelination. **(F)** EGFR and vimentin immunofluorescence staining. EGFR labels the diffuse sheet-like cellular component and the satellitosis, but not the cells within the nodule. Vimentin marks large ramified cells in the nodule and small ramified cells in the gray matter satellitosis. **(G)** BCAS1 and vimentin immunofluorescence staining showing the differential expression of these markers within the tumor. The diffuse area of the tumor (green dotted line) shows absence of BCAS1 staining, while the nodule (blue dotted line) presents BCAS1-expressing cells. Neoplastic nodular cells are larger and morphologically aberrant compared with those in the nonneoplastic areas. **(H)** EGFR immunoelectron microscopy showing EGFR label in the plasma membrane and in internal vesicles. EGFR-positive cells show abundant intermediate filaments, rough endoplasmic reticulum and mitochondria. **(I)** Vimentin immunogold labelling in the nodule area shows large cells with abundant processes and intermediate filaments. **(J)** Scheme of oligodendrocyte differentiation from immature EGFR progenitors in the ventricular-subventricular zone, vimentin positive oligodendrocyte progenitors, BCAS1-positive oligodendrocytes to Olig2 differentiated oligodendrocytes. Scale bars: **A**, Panoramics: 500 μm, GM Sheet-like, satellitosis, rosettes: 50 μm; **B**, 50 μm; **C**, 5 μm; **D**, Panoramic: 250 μm, magnifications: 50 μm; **E**, Panoramic: 250 μm, magnification: 100 μm; **F**, Panoramic: 250 μm, Nodule: 10 μm, GM sheet-like, Satellitosis, Rosettes: 50 μm, EGFR and VIM immunohistochemistry: 5 μm; **G**, Panoramic: 100 μm, Nodule: 25 μm, Neoplastic, Nonneoplastic: 10 μm; **H**, Panoramic: 2 μm, membrane detail: 500 nm, vesicle detail: 200 nm; **I**, Panoramic: 2 μm, magnification: 500 nm.

Downloaded from https://academic.oup.com/jnen/advance-article/doi/10.1093/jnen/nlaa144/6129327 by Universidad de Valencia user on 08 February 2021

TABLE List of Markers Used in Diagnostic Experiments and Tumoral Characterization

Marker Type	Marker	Method	Source	Reference (Clone)	Dilution	Sheet-like	Nodules	GM Satellitosis	WM Rosettes
Diagnostic	1p	FISH	ZytoVision (Bremerhaven, Germany)	SPEC 1p36/1q25	N/A	Deletion	Deletion	Deletion	Deletion
	19q	FISH	ZytoVision	SPEC 19q13/19p13	N/A	Deletion	Deletion	Deletion	Deletion
	IDH1	IHC	Dianova (Hamburg, Germany)	DIAH09 (H09)	1:20	Mutant	Mutant	Mutant	Mutant
	ATRX	IHC	Dianova	DIAAX1 (AX1)	1:100	Not-mutated	Not-mutated	Not-mutated	Not-mutated
Neuronal lineage	NeuN	IHC	Merck (Darmstadt, Germany)	MAB377 (A60)	1:1000	Negative	Negative	Negative	Negative
	DCX	IHC	Cell Signaling (Danvers, MI)	4604 (Polyclonal)	1:400	Negative	Negative	Negative	Negative
	Synaptophysin	IHC	DAKO (Glostrup, Denmark)	IR660 (DAK-SYNAP)	Prediluted	Negative	Negative	Negative	Negative
	TUJ1	IHC	Covance (Princeton, MA)	MMS-435P (TUJ1)	1:100	Negative	Negative	Negative	Negative
Intermediate filaments	GFAP	IHC	DAKO	IR524 (Polyclonal)	Prediluted	Positive	Negative	Negative	Negative
	GFAP	IF	Millipore (Burlington, MA)	MAB360 (GA5)	1:1000	Positive	Negative	Negative	Negative
	Vimentin	IHC	DAKO	IR630 (V9)	Prediluted	Positive	Negative	Negative	Negative
	Vimentin	IF/IG-TEM	Abcam (Cambridge, UK)	ab73159 (Polyclonal)	1:300/1:150	Negative	Positive	Positive	Negative
Oligodendroglial lineage	NaBC1(BCAS1)	IF	Santa Cruz (Dallas, TX)	sc-136342 (NaBC1 (5))	1:200	Negative	Positive	Negative	Negative
	NG2	IF/IHC	Millipore	ab5320 (Polyclonal)	1:200	Negative	Negative	Negative	Negative
	Olig2	IHC	Gennova Scientific (Seville, Spain)	AP10616 (211F1.1)	1:50	Positive	Positive	Positive	Positive
Proliferation markers	Ki67	IHC	DAKO	IR626 (MIB-1)	Prediluted	Negative	Positive	Negative	Positive
	c-MYC	IHC	Biocare Medical (Pacheco, CA)	415 (EP121)	1:50	Negative	Positive	Negative	Positive
	MYC	FISH	Agilent (Princeton, MA)	G-11623-2	N/A	Negative	Positive	Negative	Positive
	MYCN	FISH	Kreatech (Wetzlar, Germany)	KI-10706	N/A	Negative	Negative	Negative	Negative
Growth factors	EGFR	IHC	DAKO	M7239 (E-30)	1:50	Positive	Negative	Positive	Positive
	EGFR	IF/IG-TEM	Millipore	06-847 (Polyclonal)	1:200/1:100	Negative	Negative	Negative	Negative
	PDGFRa	IHC	BD Biosciences (San Diego, CA)	556001 (aR1)	1:50	Negative	Negative	Negative	Negative

Marker expression in the different tumor areas is shown.
Abbreviations: FISH, fluorescent in situ hybridization; IF, immunofluorescence; IG-TEM, immuno-gold electron microscopy; IHC, immunohistochemistry.

Downloaded from https://academic.oup.com/jnen/advance-article/doi/10.1093/jnen/nlaa144/6129327 by Universidad de Valencia user on 08 February 2021

(PROMETEO/2019/075) to J.M.G.V. and by the Spanish Ministry of Science, Innovation and Universities (PCI2018-093062) to V.H.P.

COMPETING INTERESTS

The authors have no duality or conflicts of interest to declare.

ACKNOWLEDGMENTS

All procedures followed were in accordance with the ethical standards of the responsible committee on human experimentation (institutional and national) and with the Helsinki Declaration of 1964 and its later amendments. Informed consent was obtained from all patients for being included in the study. The authors acknowledge the support of Patricia García-Tárraga at the Laboratory of Comparative Neurobiology of the University of Valencia.

REFERENCES

1. Reifenberger G, Collins VP, Hartmann C, et al. Oligodendroglioma, IDH-mutant and 1p/19q-codeleted. In: Louis DN, Ohgaki H, Wiestler OD, Cavenee WK, ed. WHO Classification of Tumours of the Central Nervous System. Lyon, France: International Agency for Research on Cancer 2016:60–9
2. Wesseling P, van den Bent M, Perry A. Oligodendroglioma: Pathology, molecular mechanisms and markers. Acta Neuropathol 2015;129:809–27
3. Wesseling P, Capper D. WHO 2016 Classification of gliomas. Neuropathol Appl Neurobiol 2018;44:139–50
4. Canoll P, Goldman JE. The interface between glial progenitors and gliomas. Acta Neuropathol 2008;116:465–77
5. Shoshan Y, Nishiyama A, Chang A, et al. Expression of oligodendrocyte progenitor cell antigens by gliomas: Implications for the histogenesis of brain tumors. Proc Natl Acad Sci USA 1999;96:10361–6
6. Persson AI, Petritsch C, Swartling FJ, et al. Non-stem cell origin for oligodendroglioma. Cancer Cell 2010;18:669–82
7. Zong H, Verhaak RGW, Canoll P. The cellular origin for malignant glioma and prospects for clinical advancements. Expert Rev Mol Diagn 2012;12:383–94
8. Kamoun A, Idbaih A, Dehais C, et al. Integrated multi-omics analysis of oligodendroglial tumours identifies three subgroups of 1p/19q co-deleted gliomas. Nat Commun 2016;7:11263.
9. Bielle F, Ducray F, Mokhtari K, et al. Tumor cells with neuronal intermediate progenitor features define a subgroup of 1p/19q co-deleted anaplastic gliomas. Brain Pathol 2017;27:567–79.
10. Fard MK, van der Meer F, Sánchez P, et al. BCAS1 expression defines a population of early myelinating oligodendrocytes in multiple sclerosis lesions. Sci Transl Med 2017;9:eaam7816
11. Lindberg N, Kastemar M, Olofsson T, et al. Oligodendrocyte progenitor cells can act as cell of origin for experimental glioma. Oncogene 2009; 28:2266–75
12. Gorris R, Fischer J, Erwes KL, et al. Pluripotent stem cell-derived radial glia-like cells as stable intermediate for efficient generation of human oligodendrocytes. Glia 2015;63:2152–67
13. Aguirre A, Dupree JL, Mangin JM, et al. A functional role for EGFR signaling in myelination and remyelination. Nat Neurosci 2007;10: 990–1002
14. Doetsch F, Petreanu L, Caille I, et al. EGF converts transit-amplifying neurogenic precursors in the adult brain into multipotent stem cells. Neuron 2002;36:1021–34
15. Dougherty JD, Fomchenko EI, Akuffo AA, et al. Candidate pathways for promoting differentiation or quiescence of oligodendrocyte progenitor-like cells in glioma. Cancer Res 2012;72:4856–68

Downloaded from https://academic.oup.com/jnen/advance-article/doi/10.1093/jnen/nlaa144/6129327 by Universidad de Valencia user on 08 February 2021